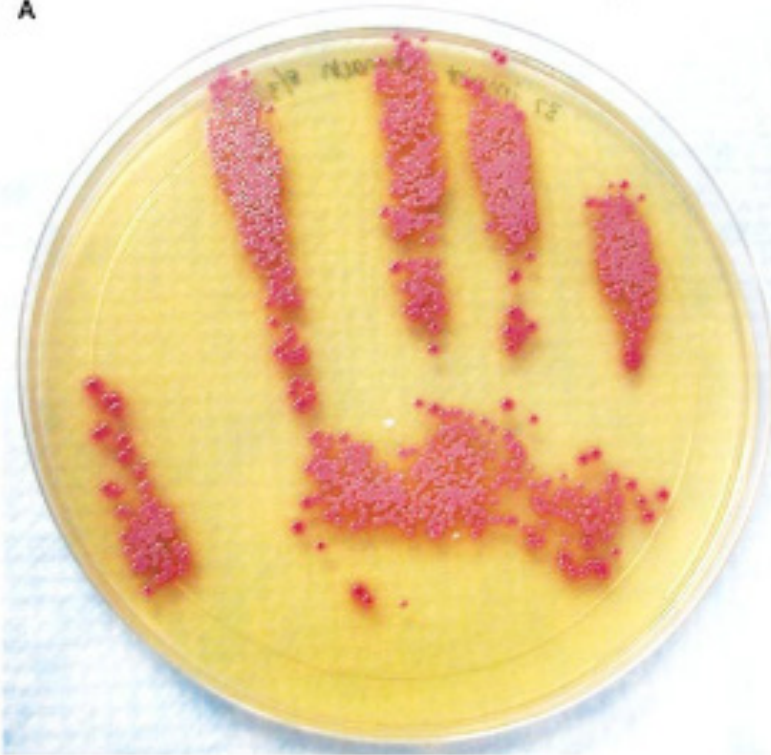

Infectious Disease Clinical Images

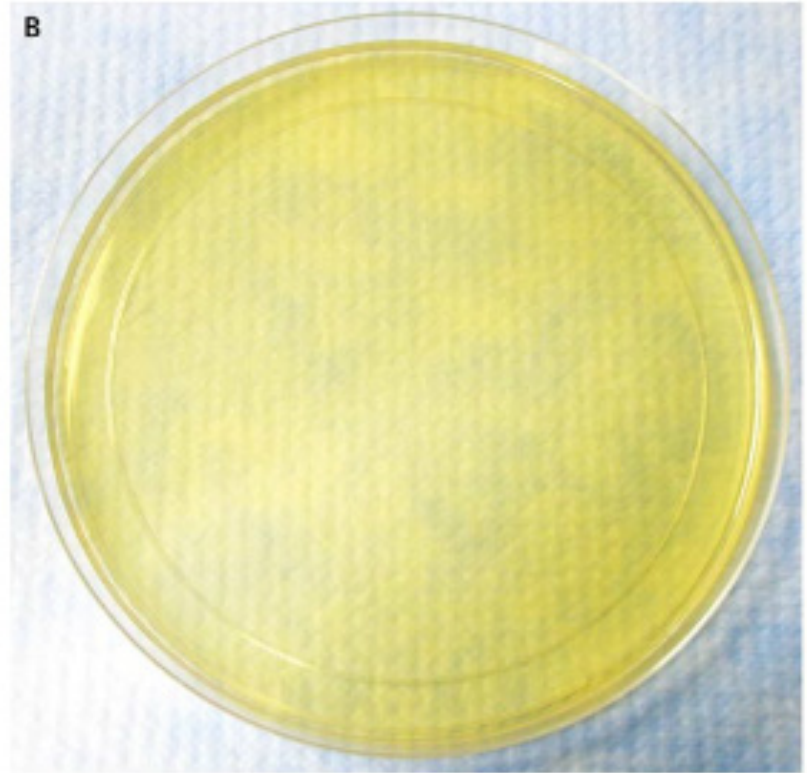
NEJM 2009 and 2010

MRSA Hand Print

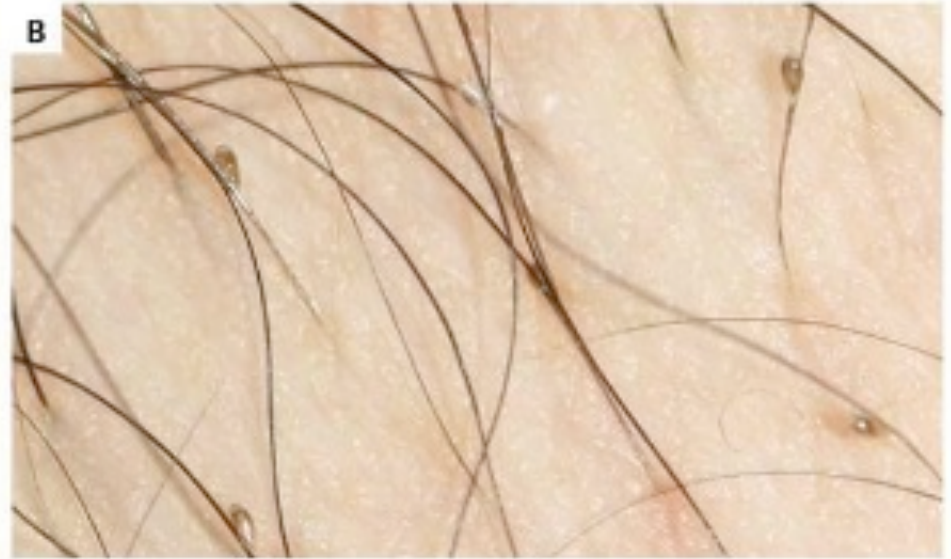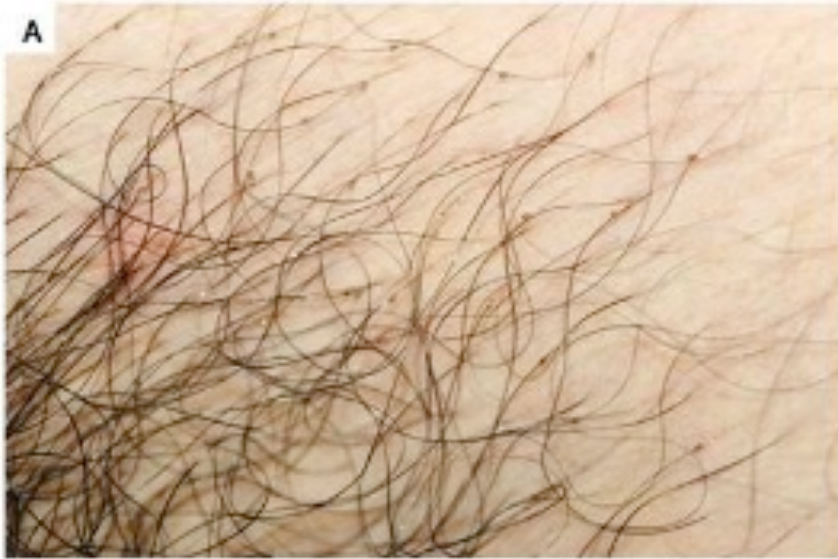A



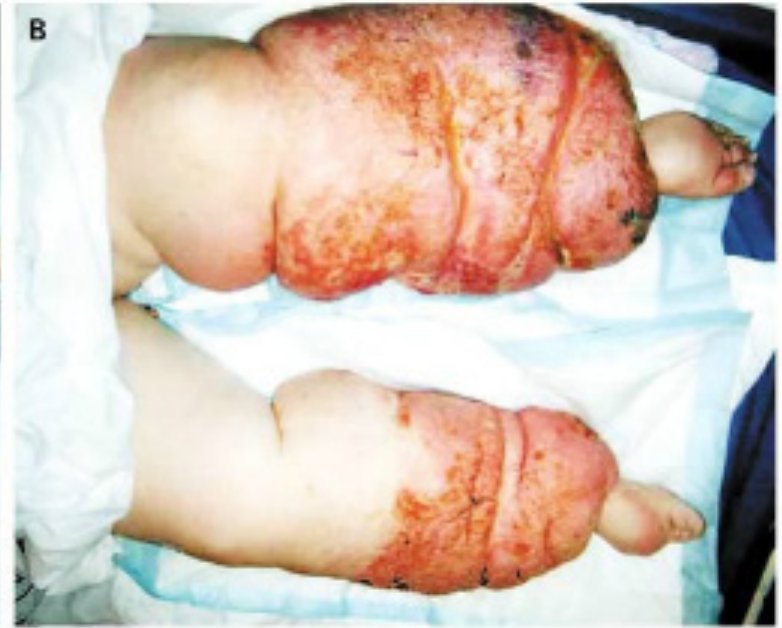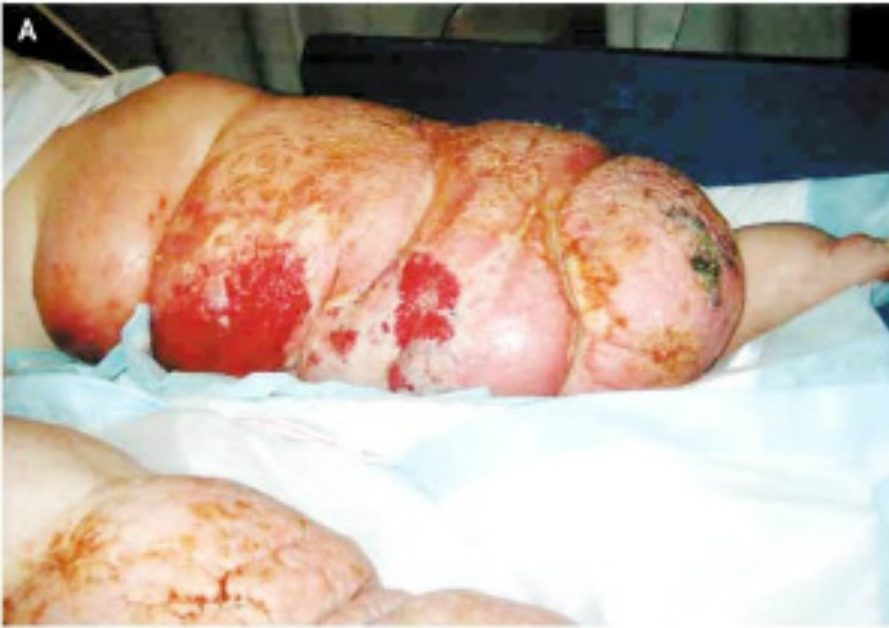B



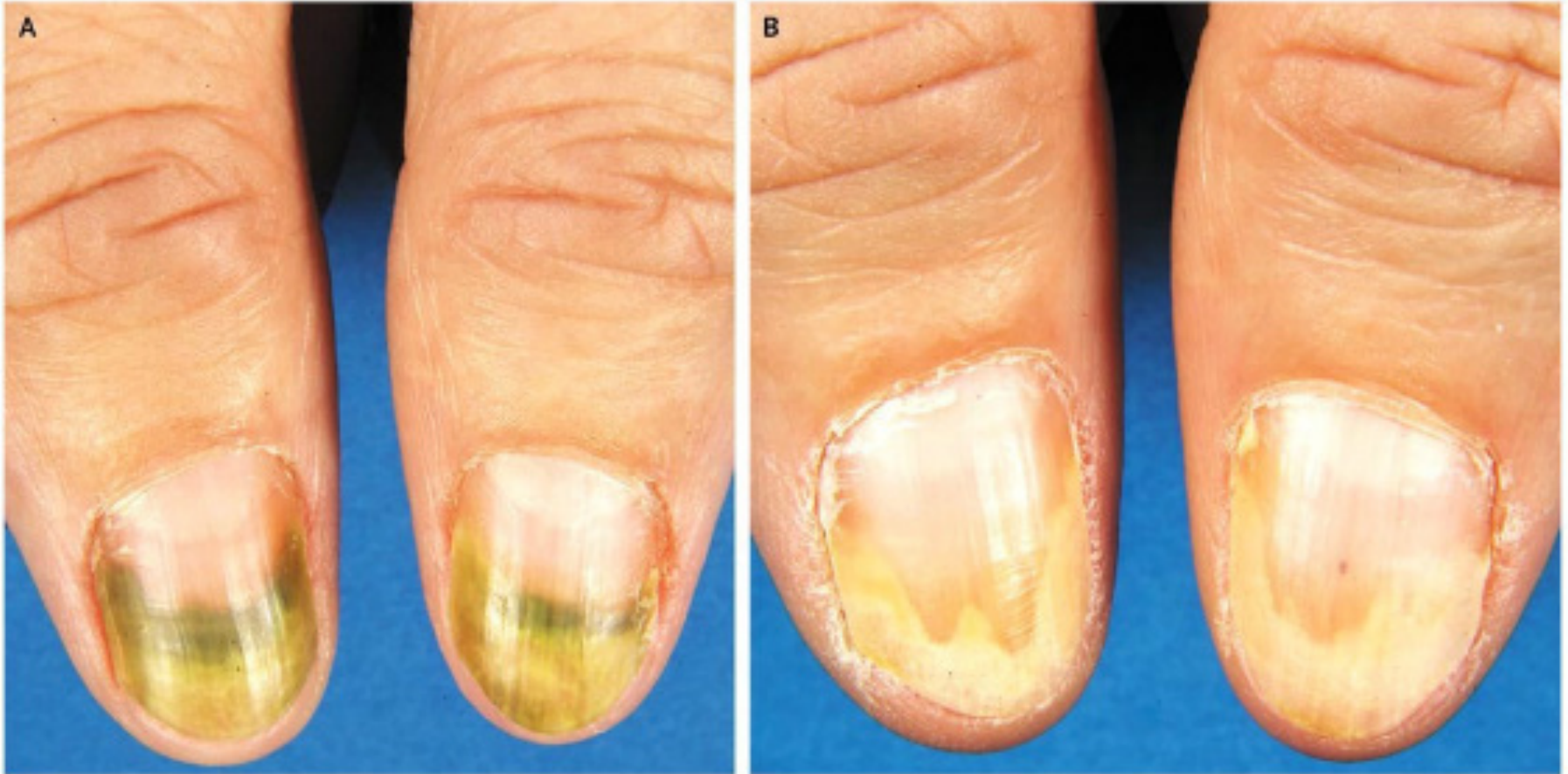Pubic Pediculosis



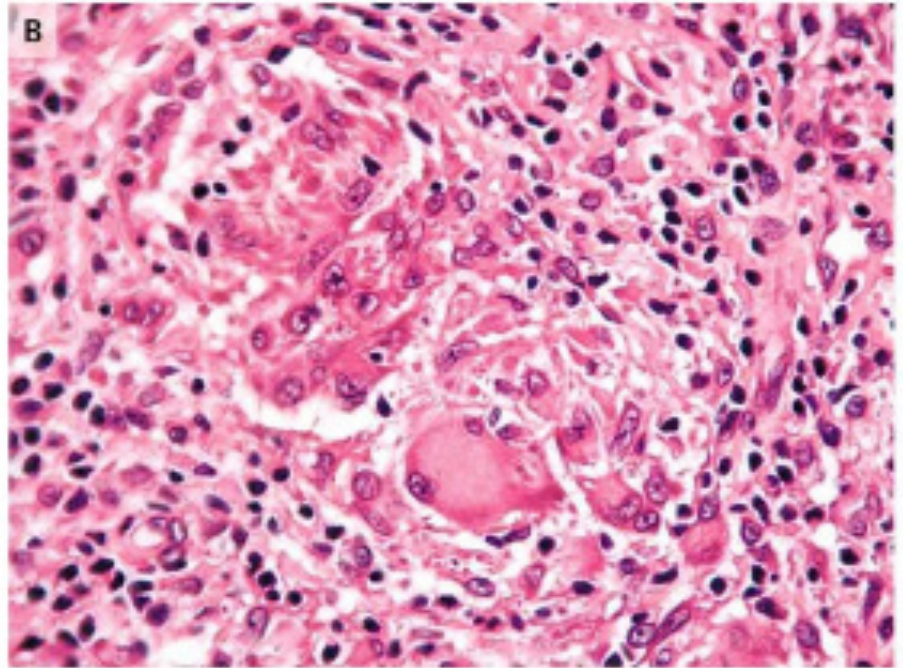
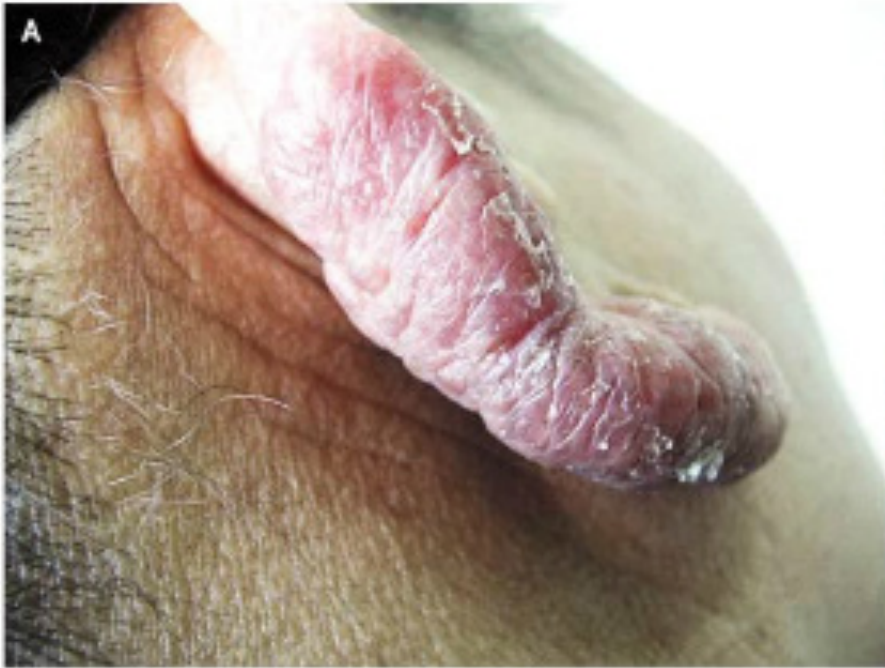Lymphedema Tarda



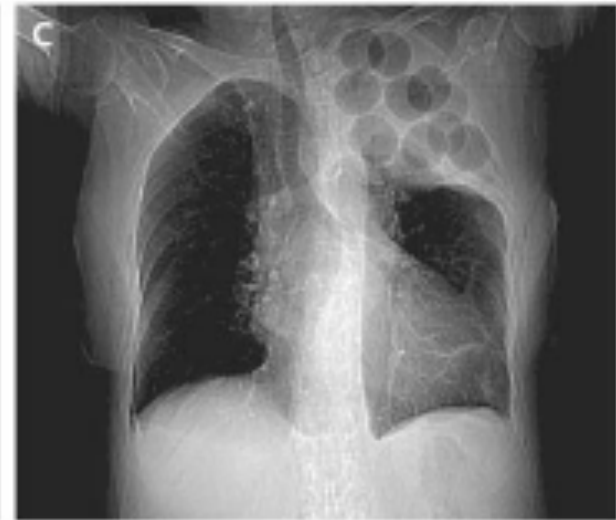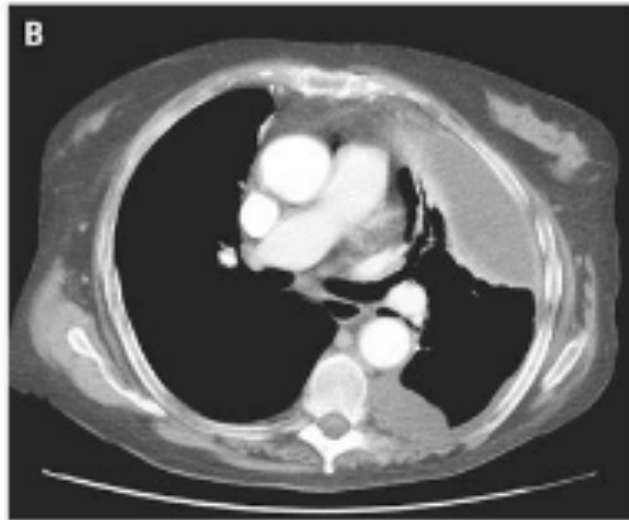
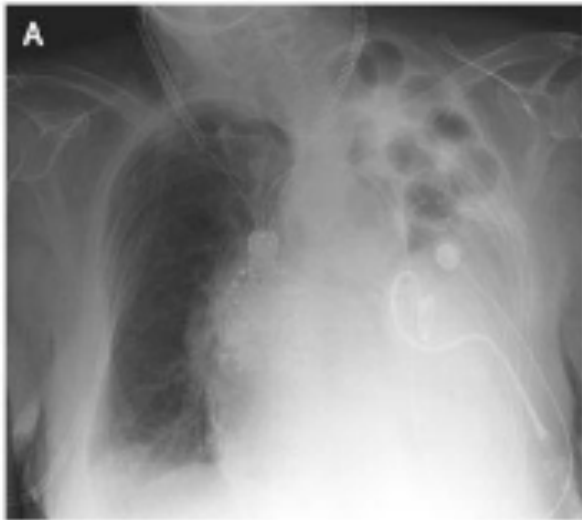Green Nails



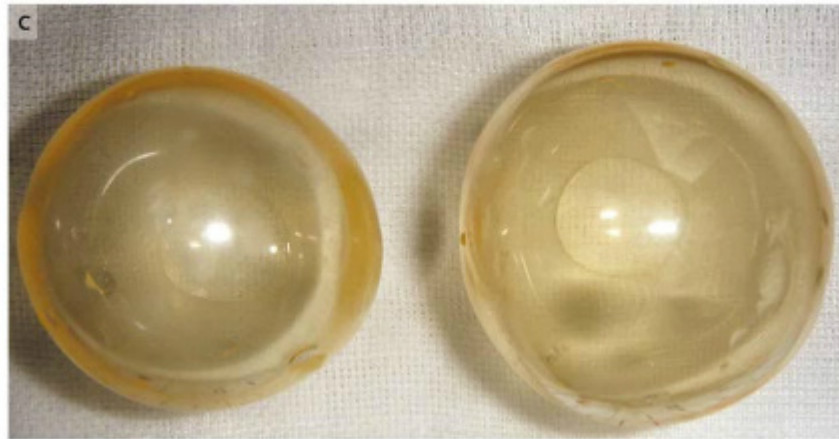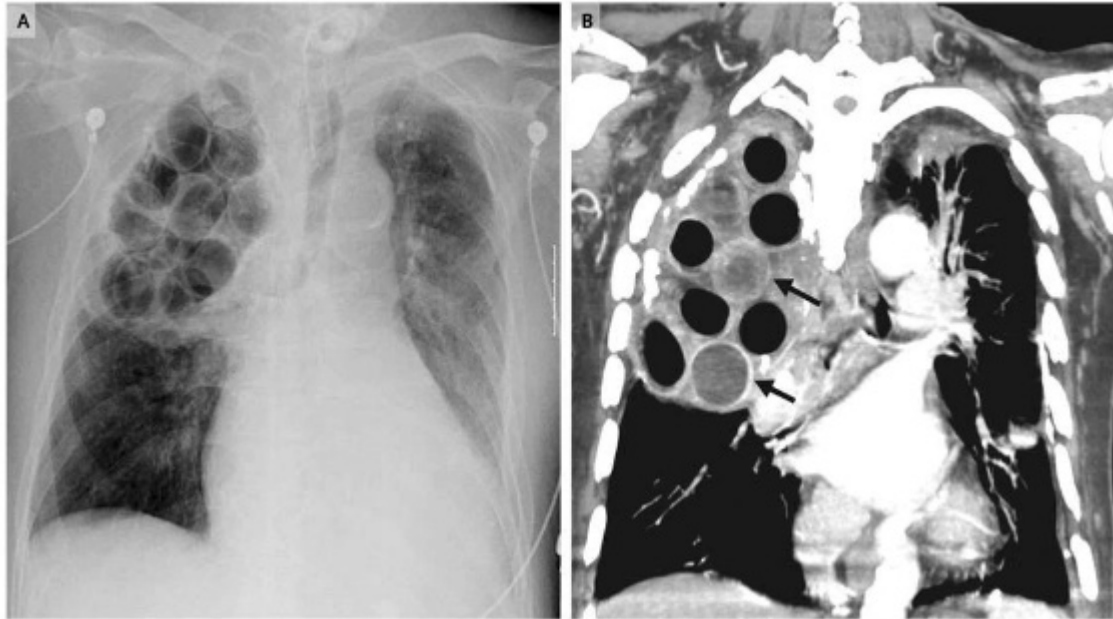
Lupoid Leishmaniasis



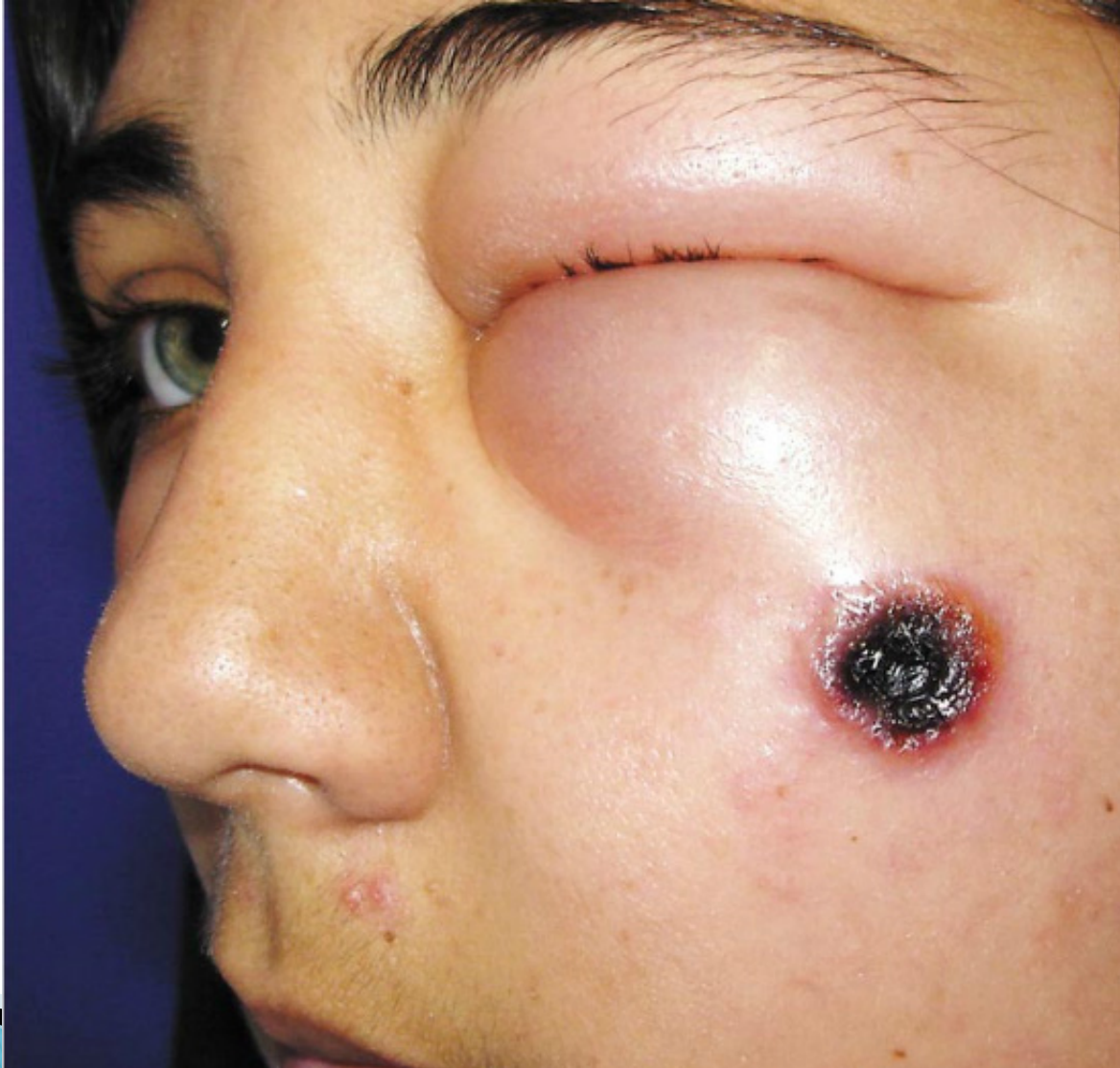Plombage Cavities



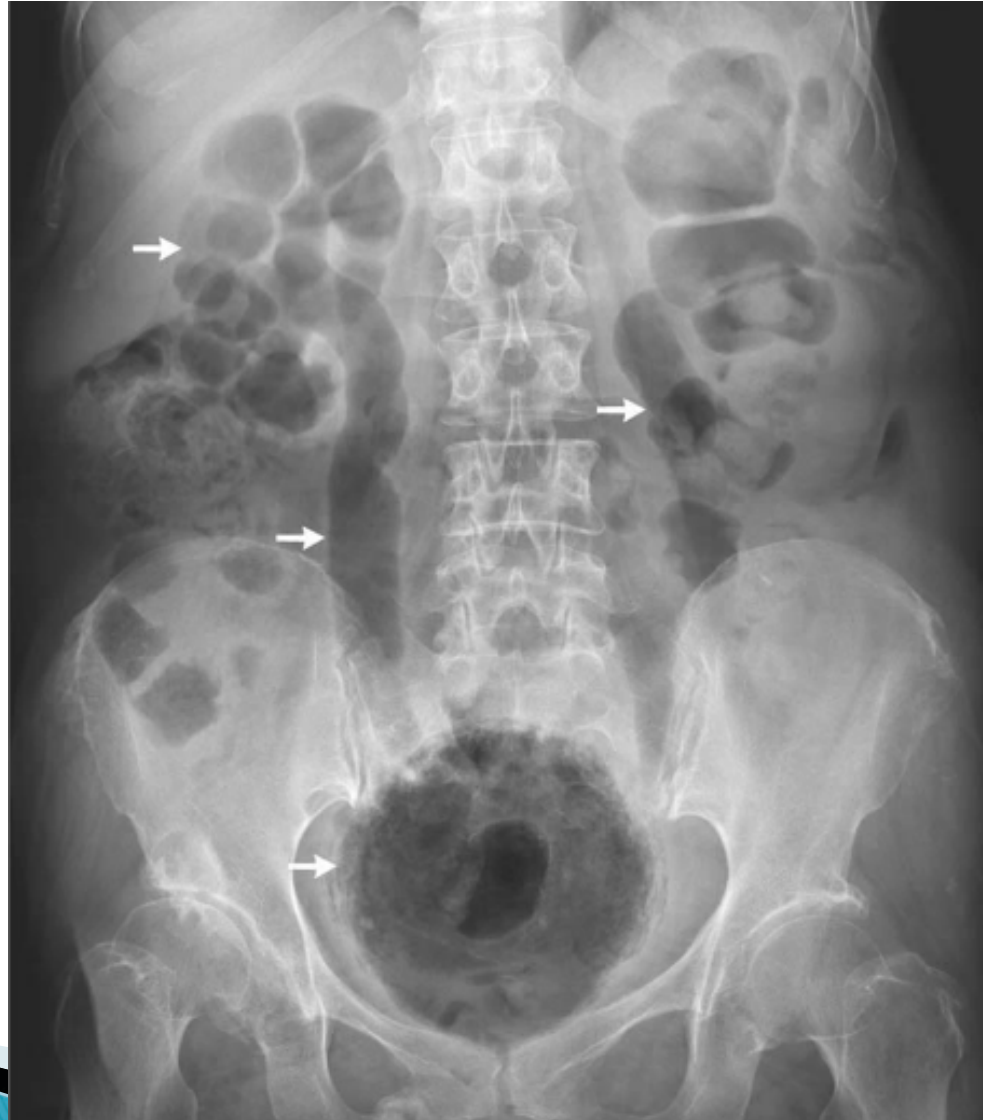Plombage Cavities (cont.)



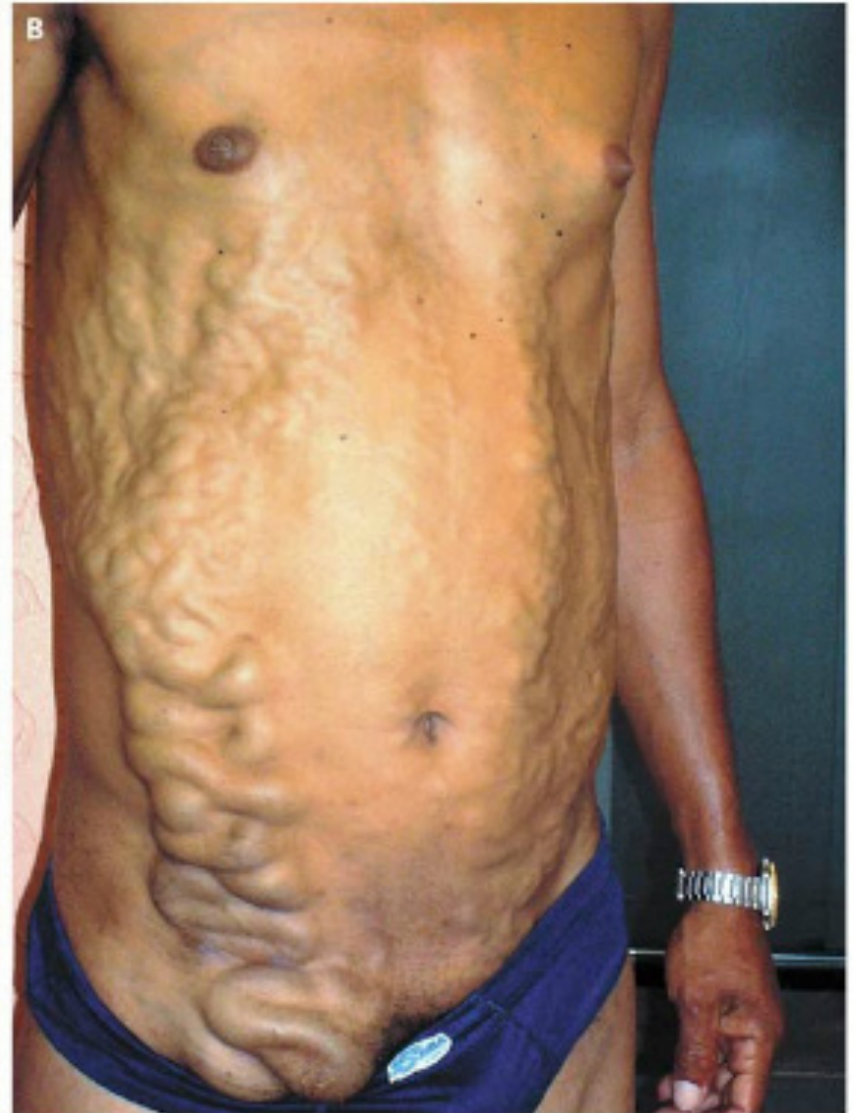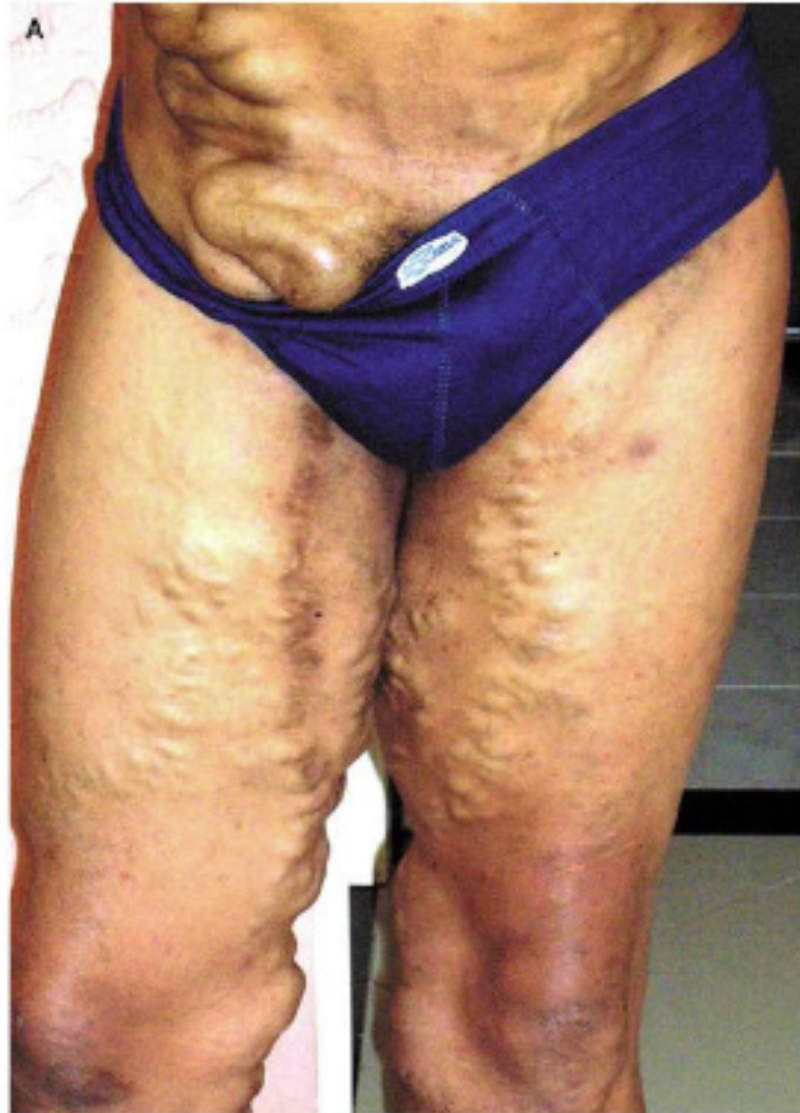Cutaneous Anthrax



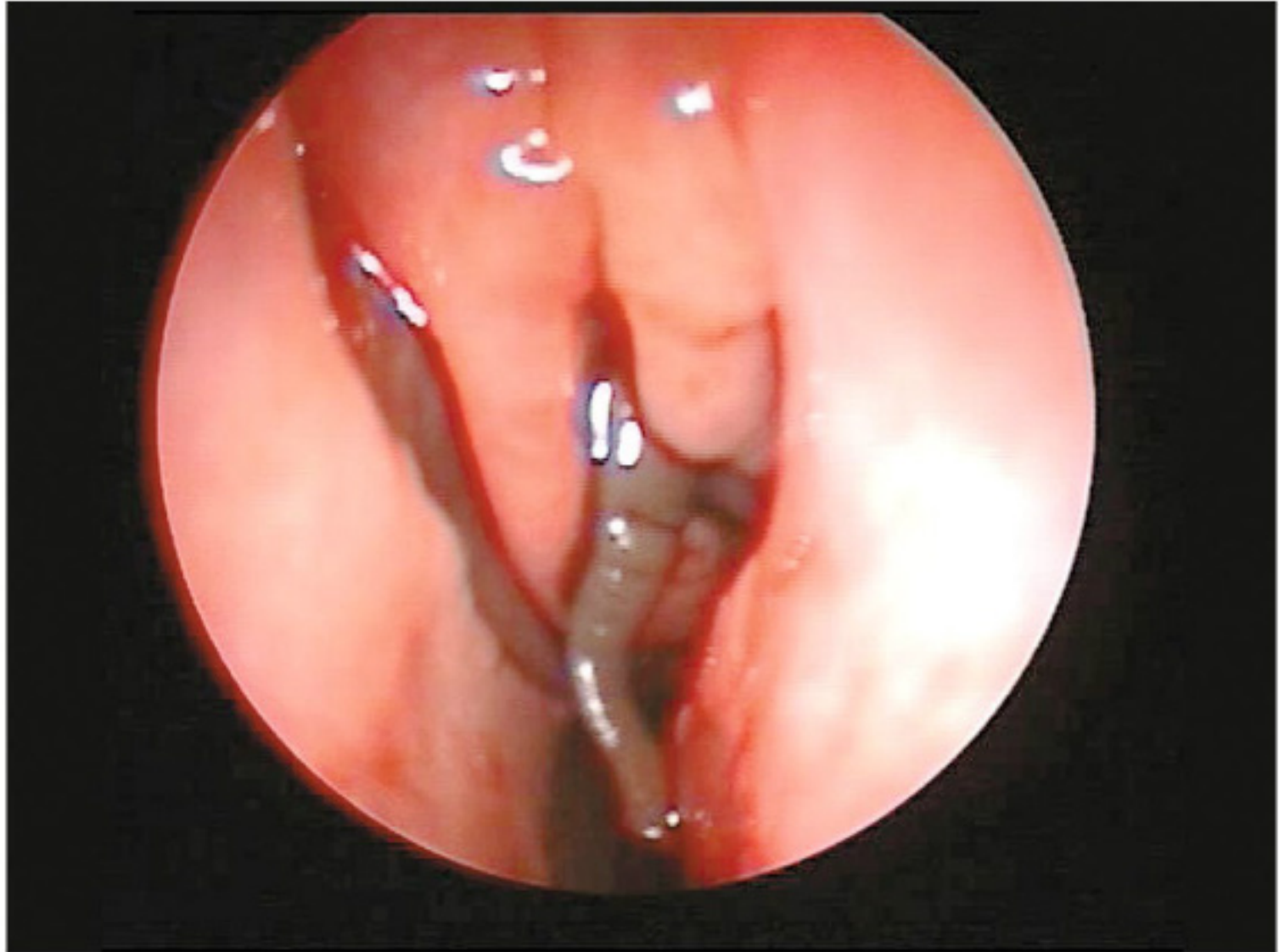
Emphysematous Cystitis



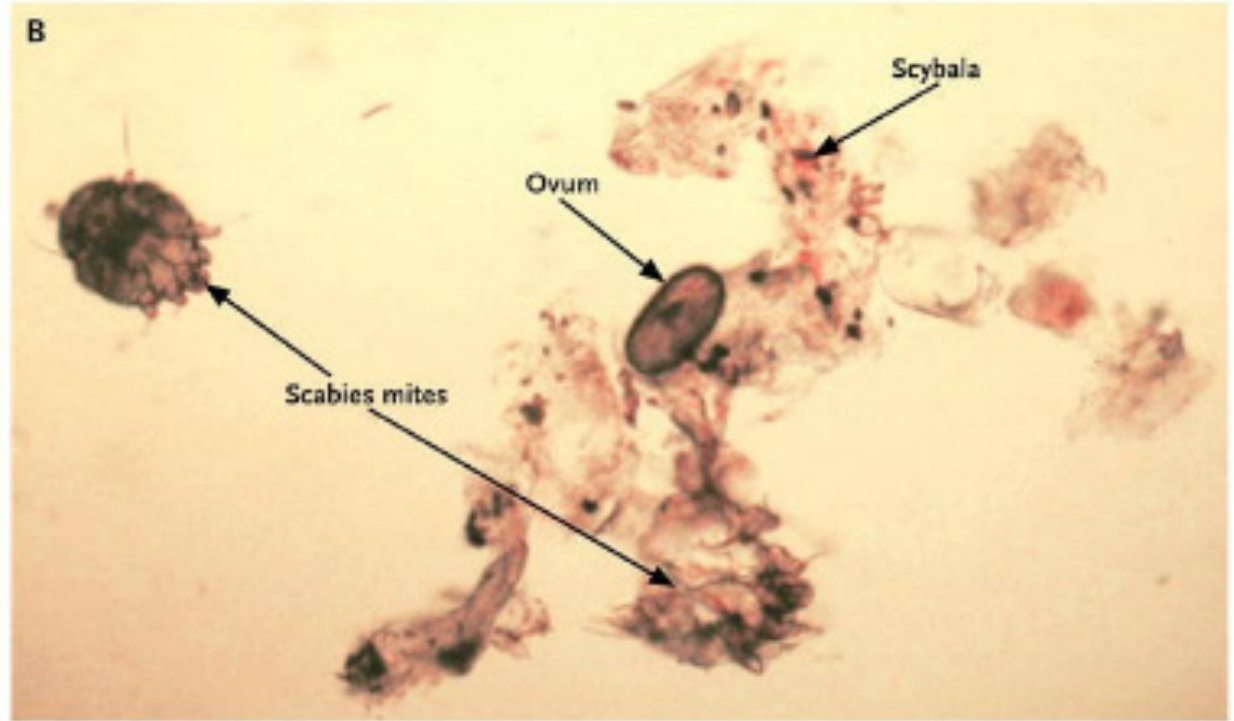
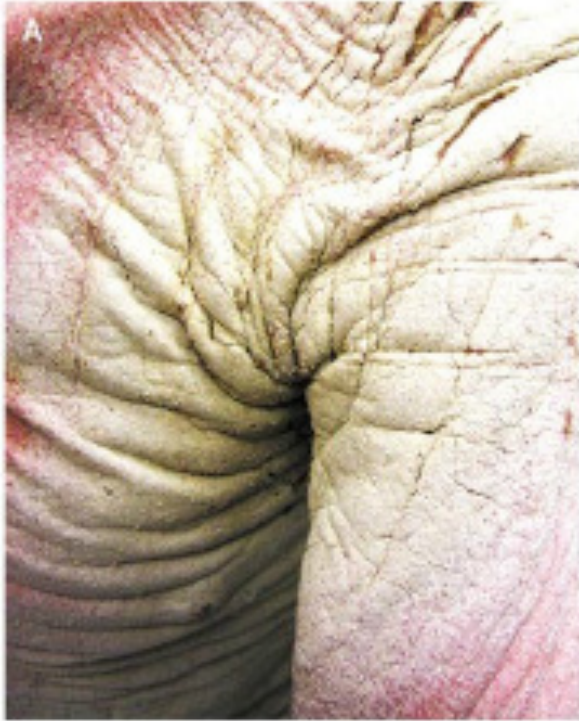Varicosities in Chronic Schistomoniasis



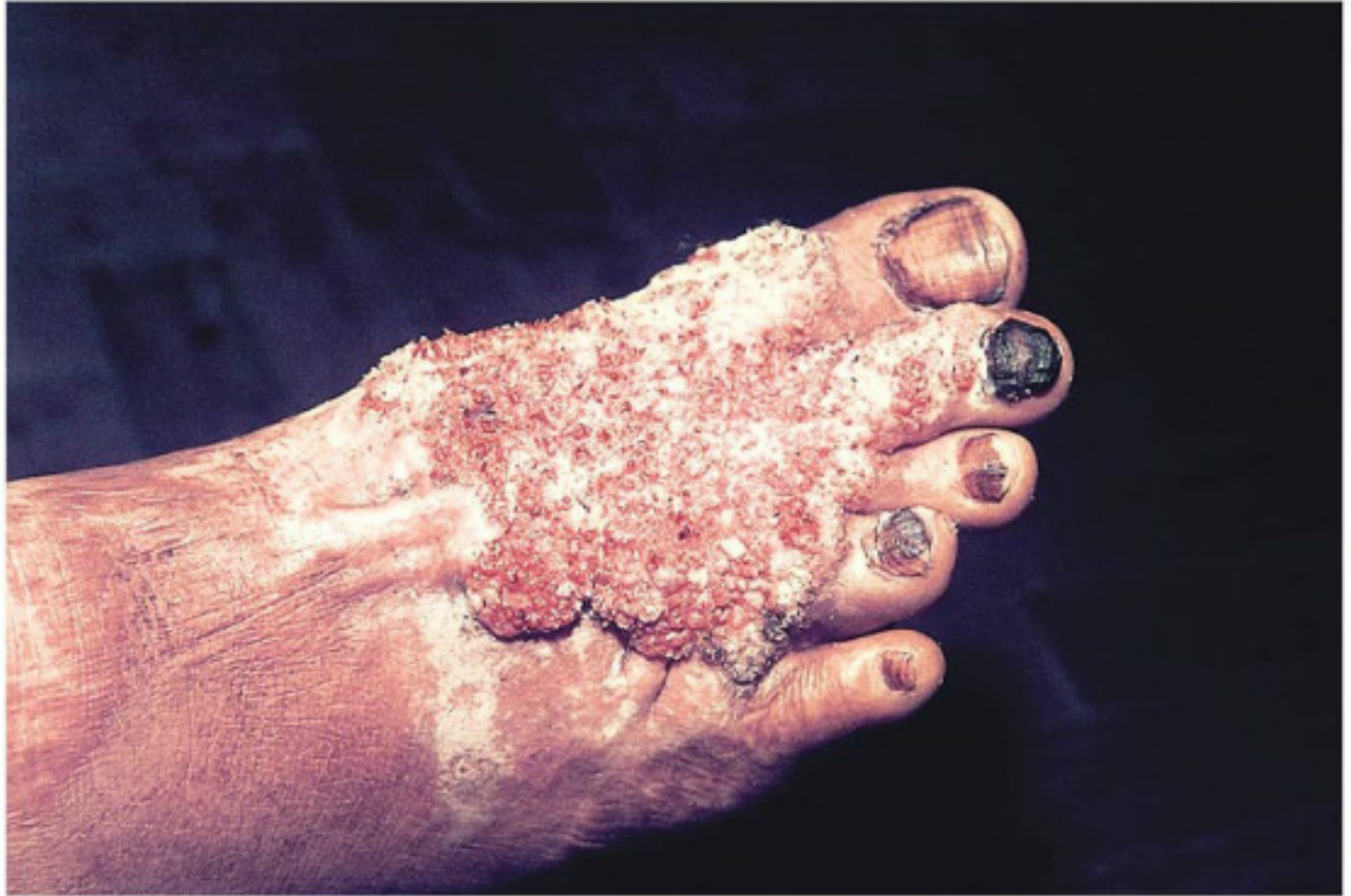Epistaxis Due to Nasal Leech



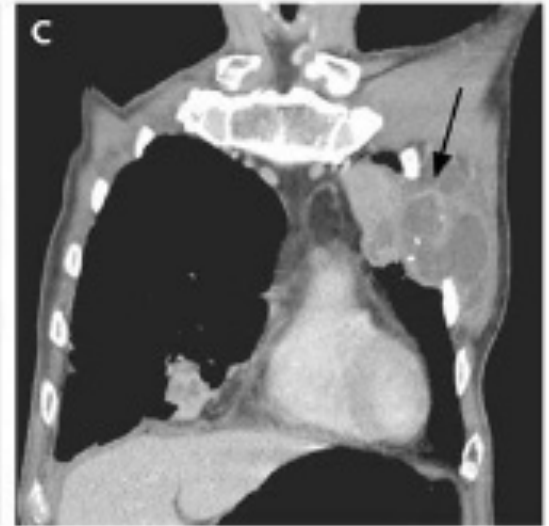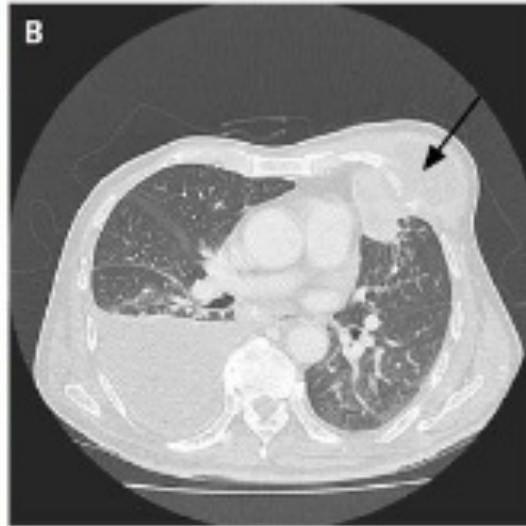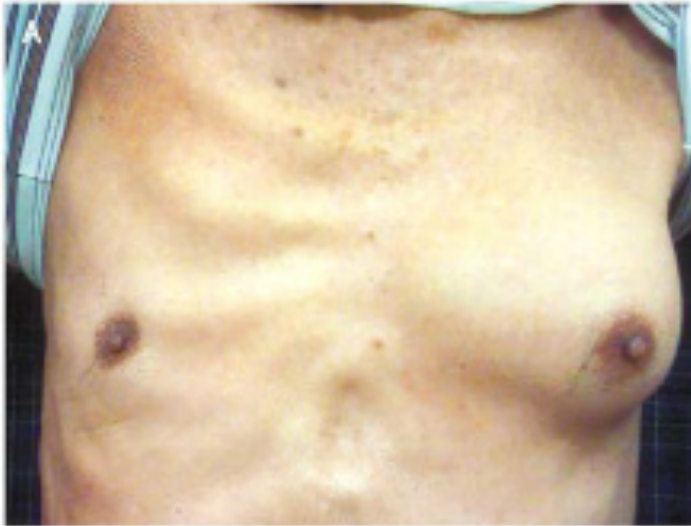Pachyderma



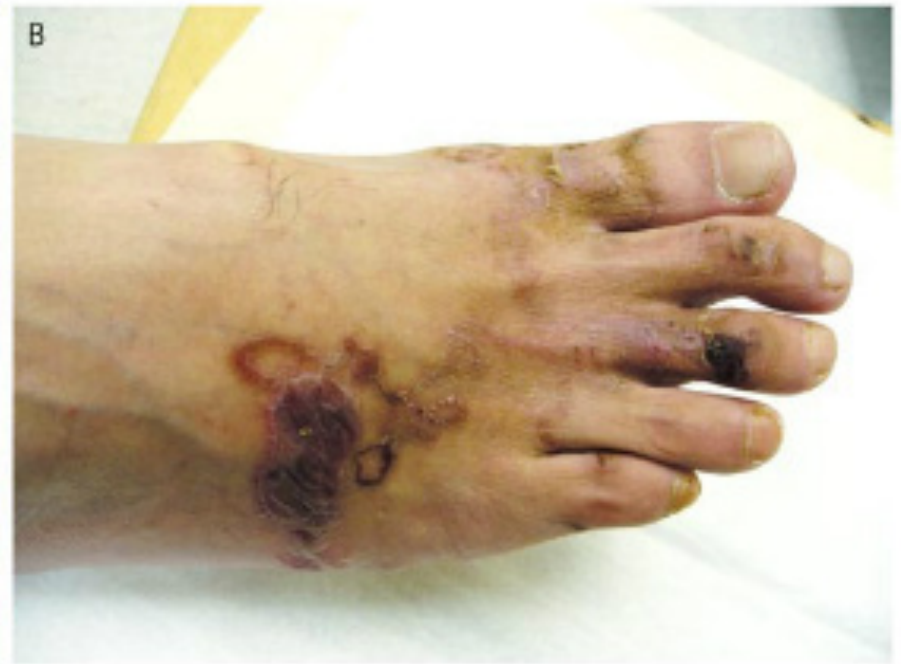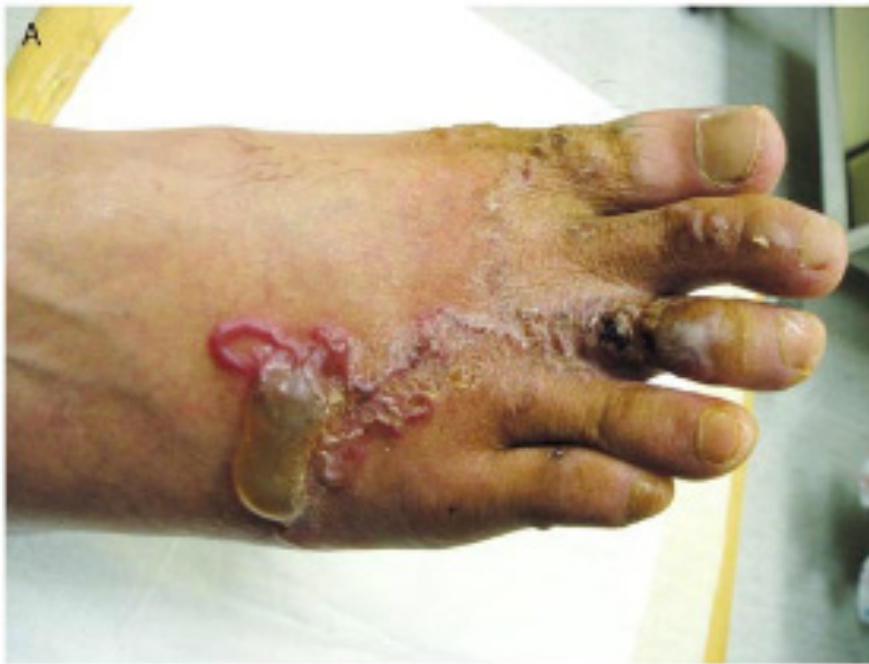Chromoblastomycosis



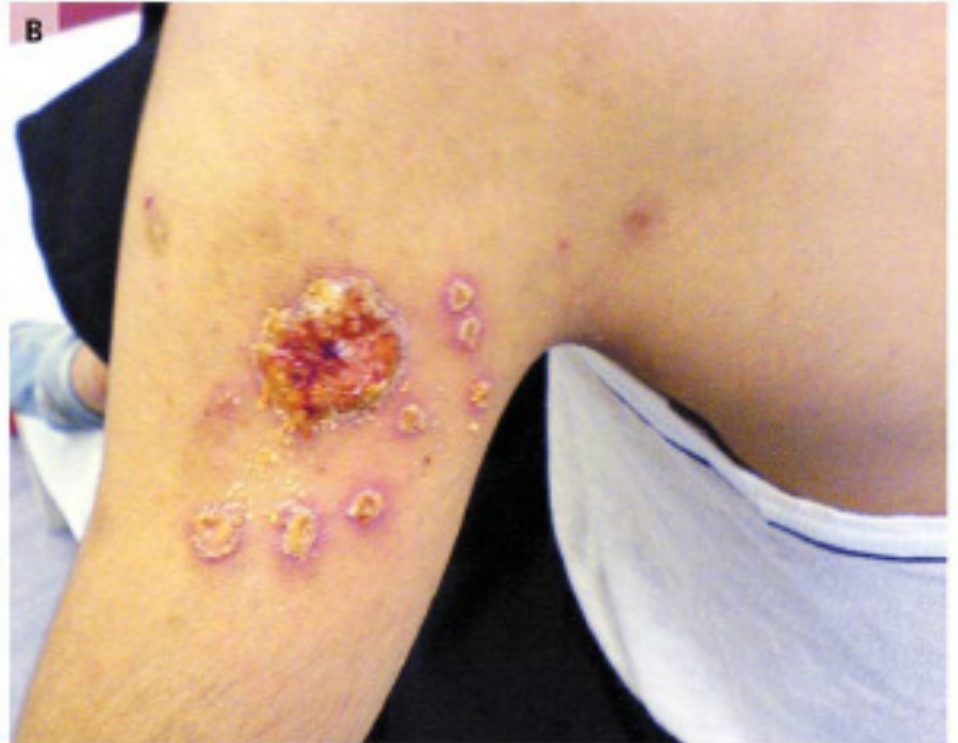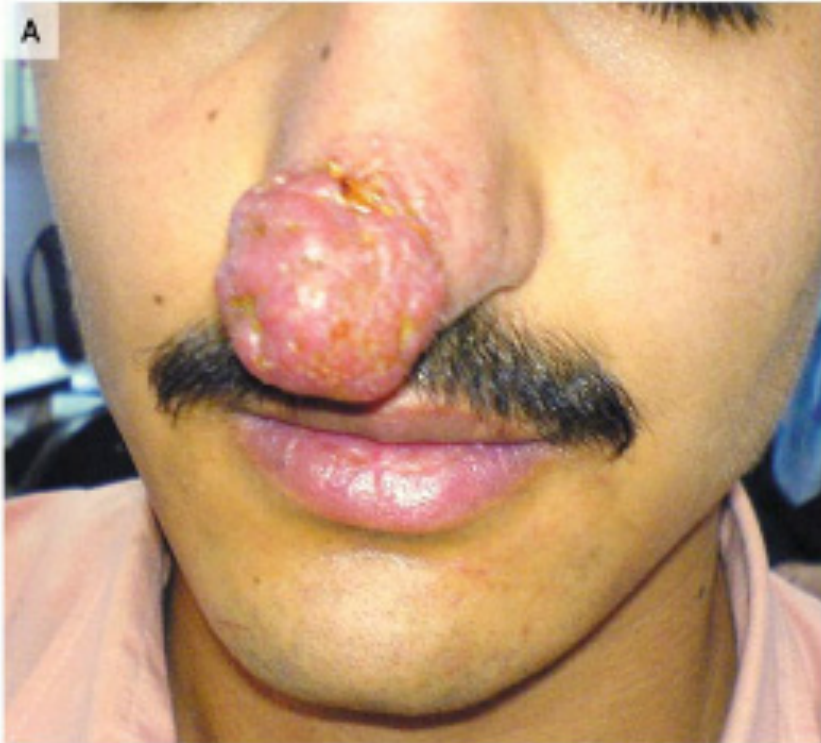Gynecomastia c/b TB Abscess



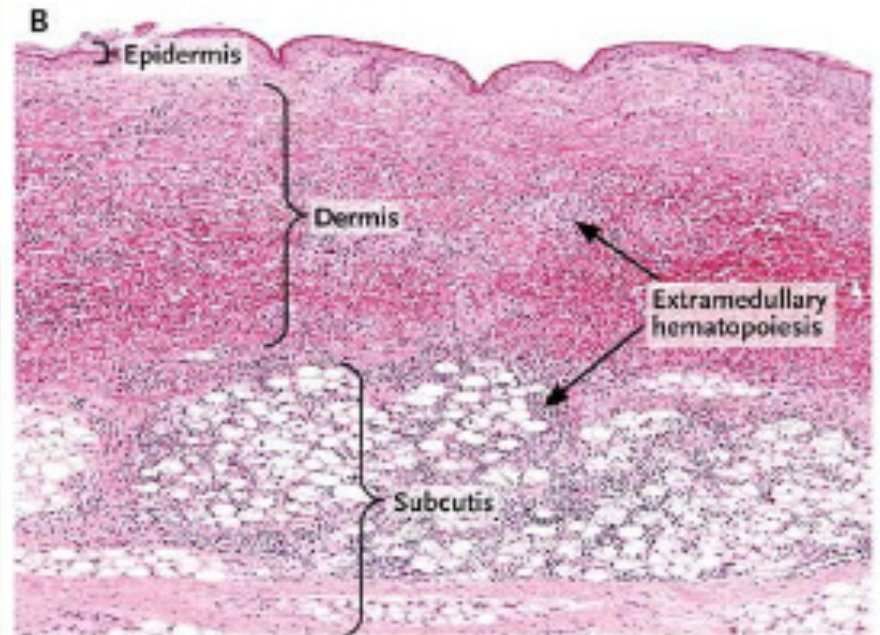
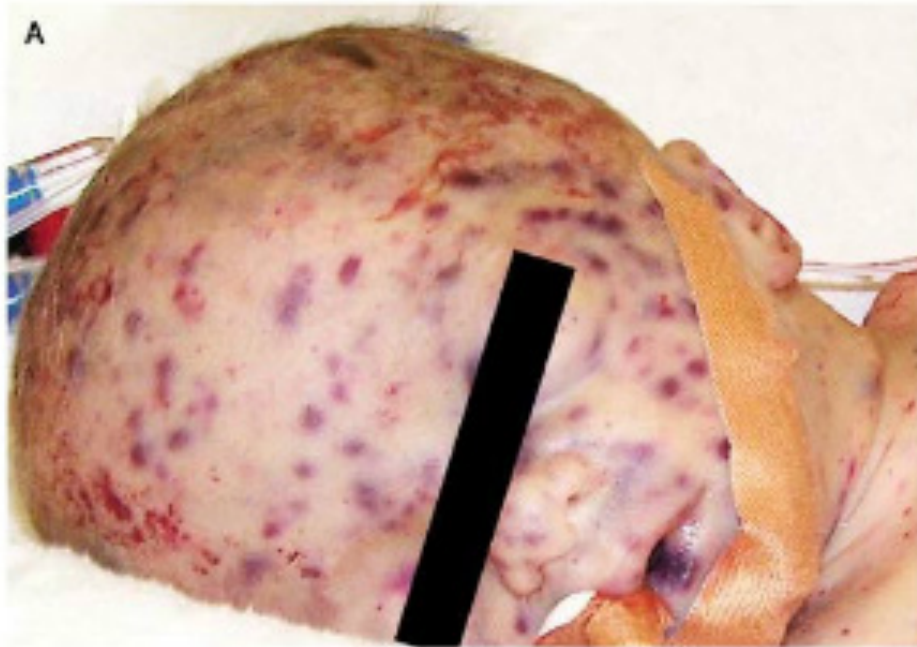
Cutaneous Larva Migrans



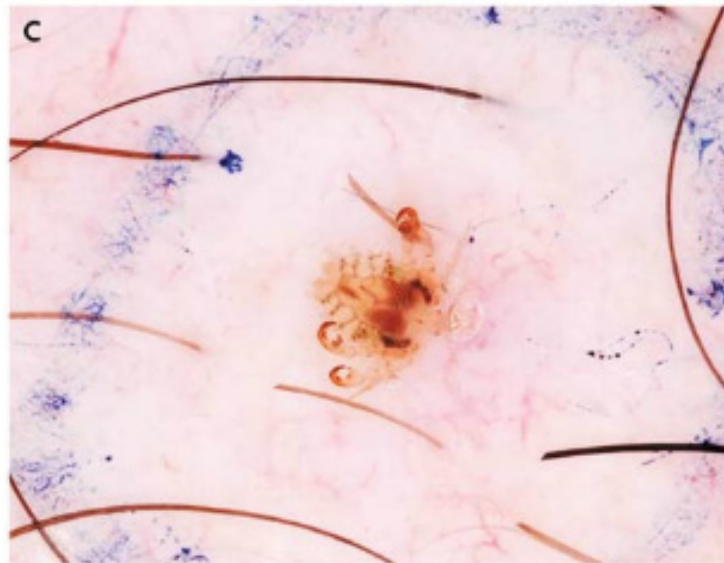
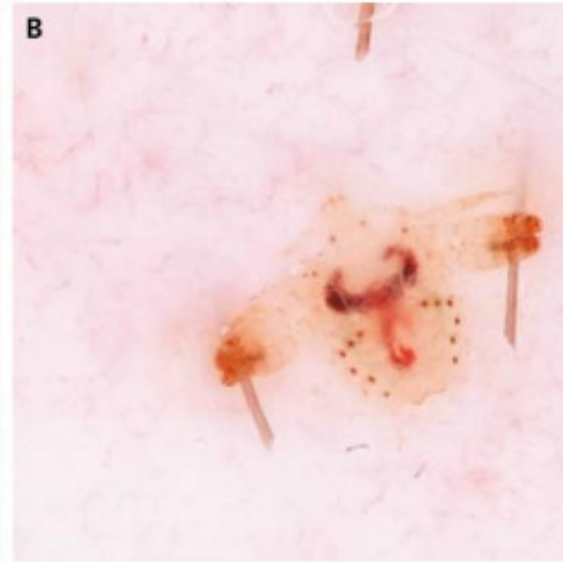
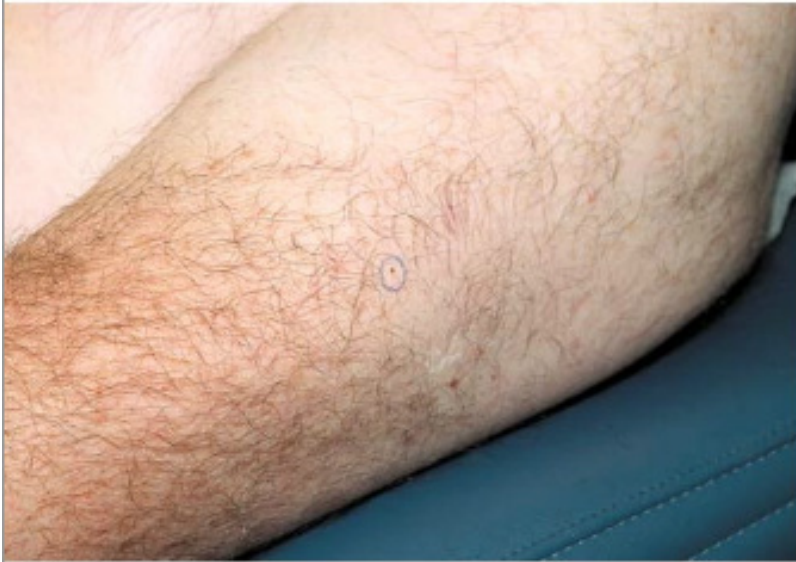Cutaneous Leishmaniasis



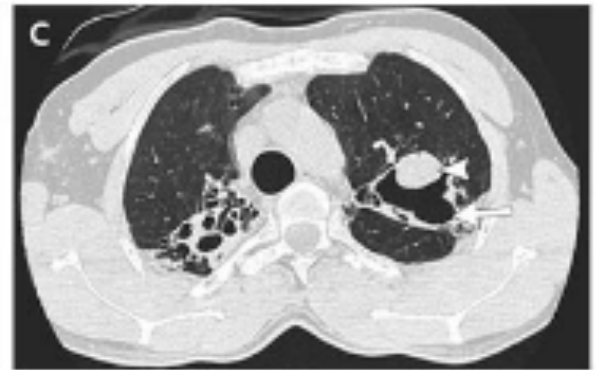
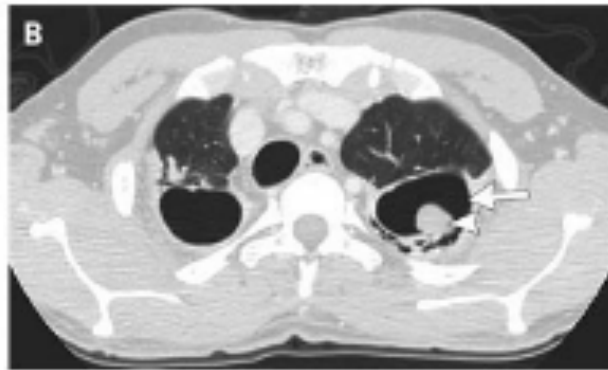
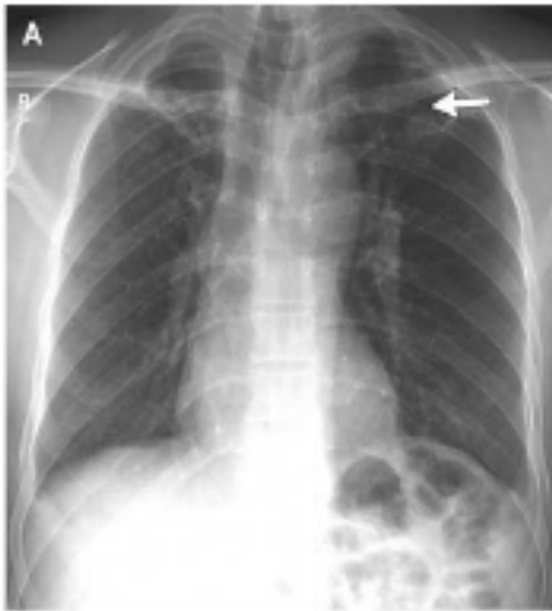
Congenital CMV



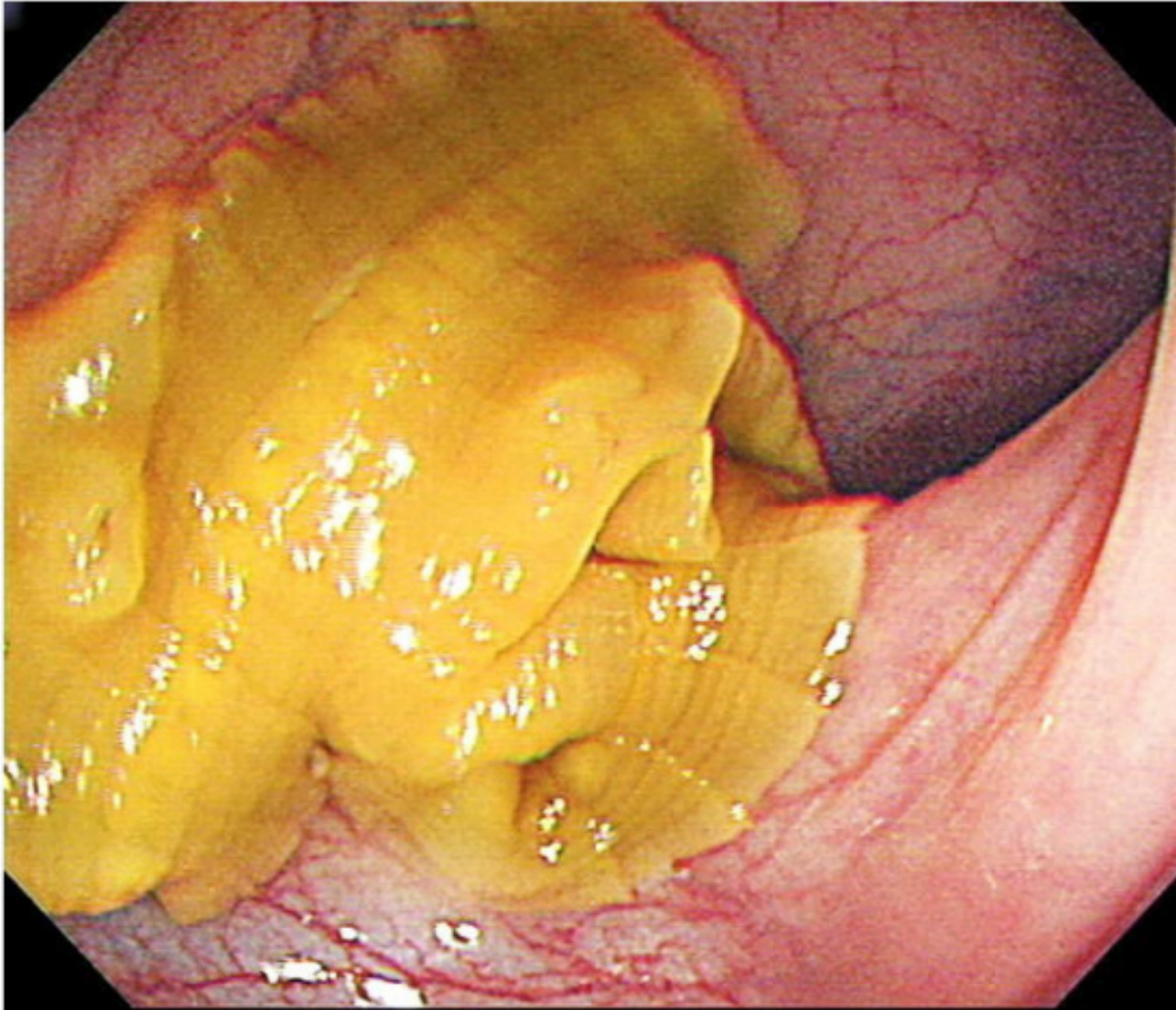
Phthiriasis



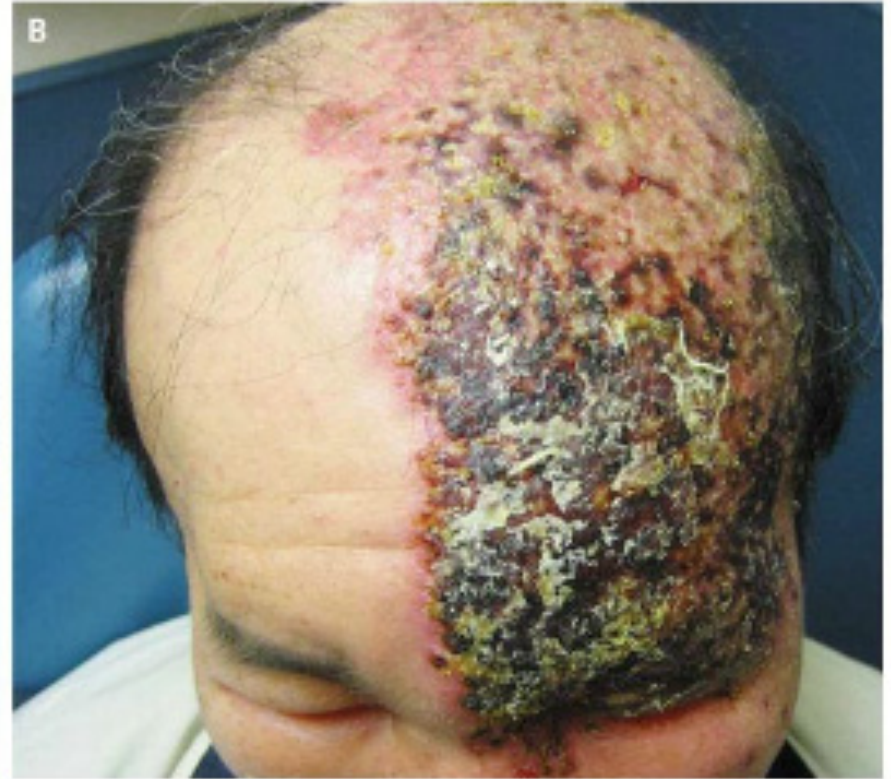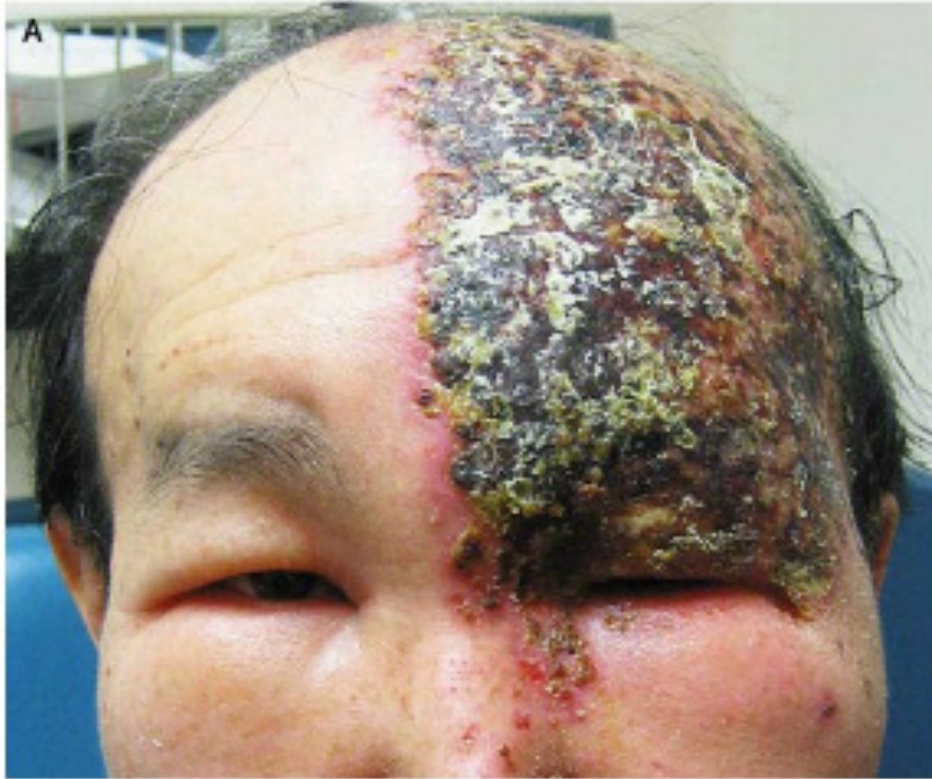Aspergilloma



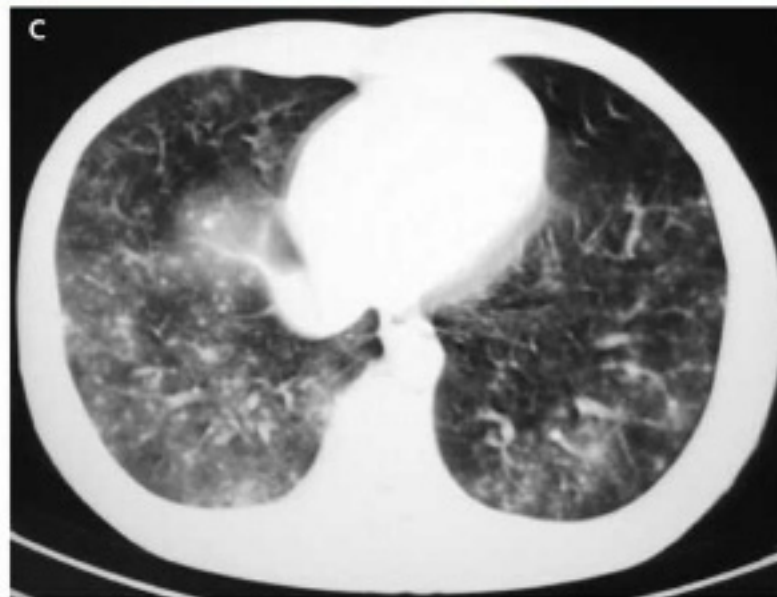
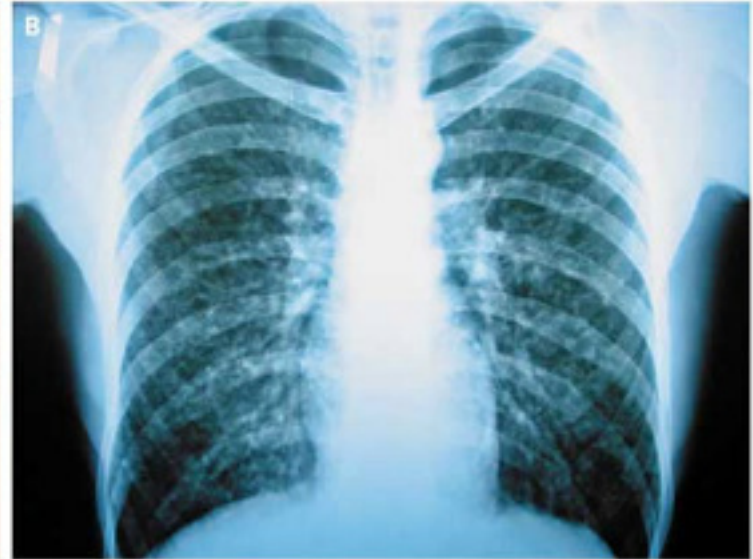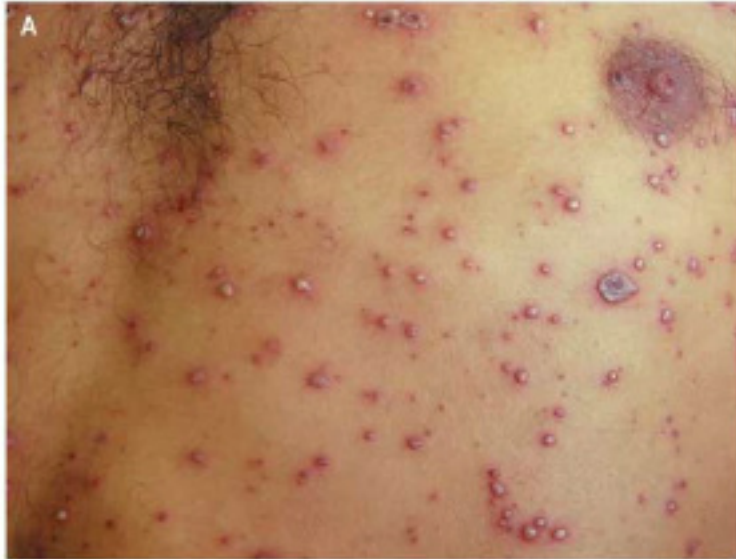Diphyllobothrium latum



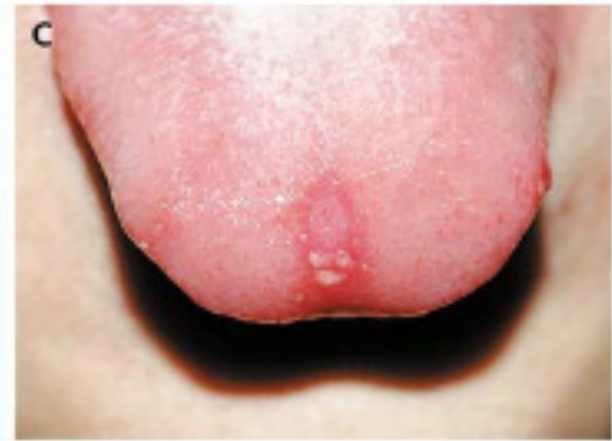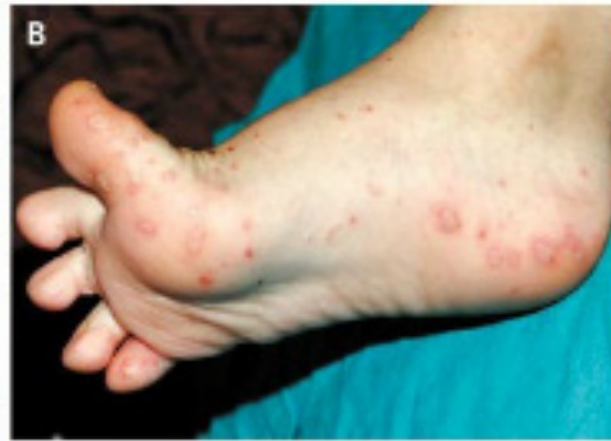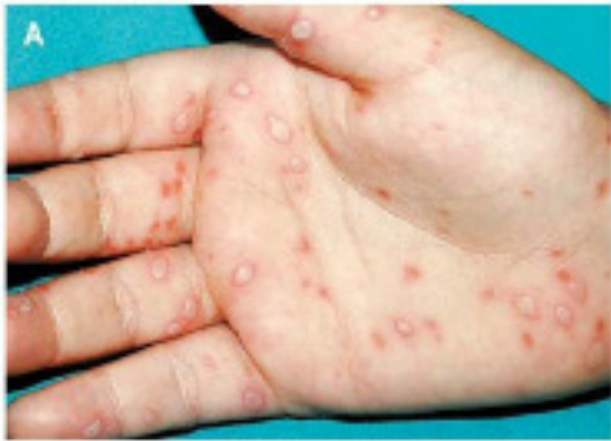Herpes Zoster



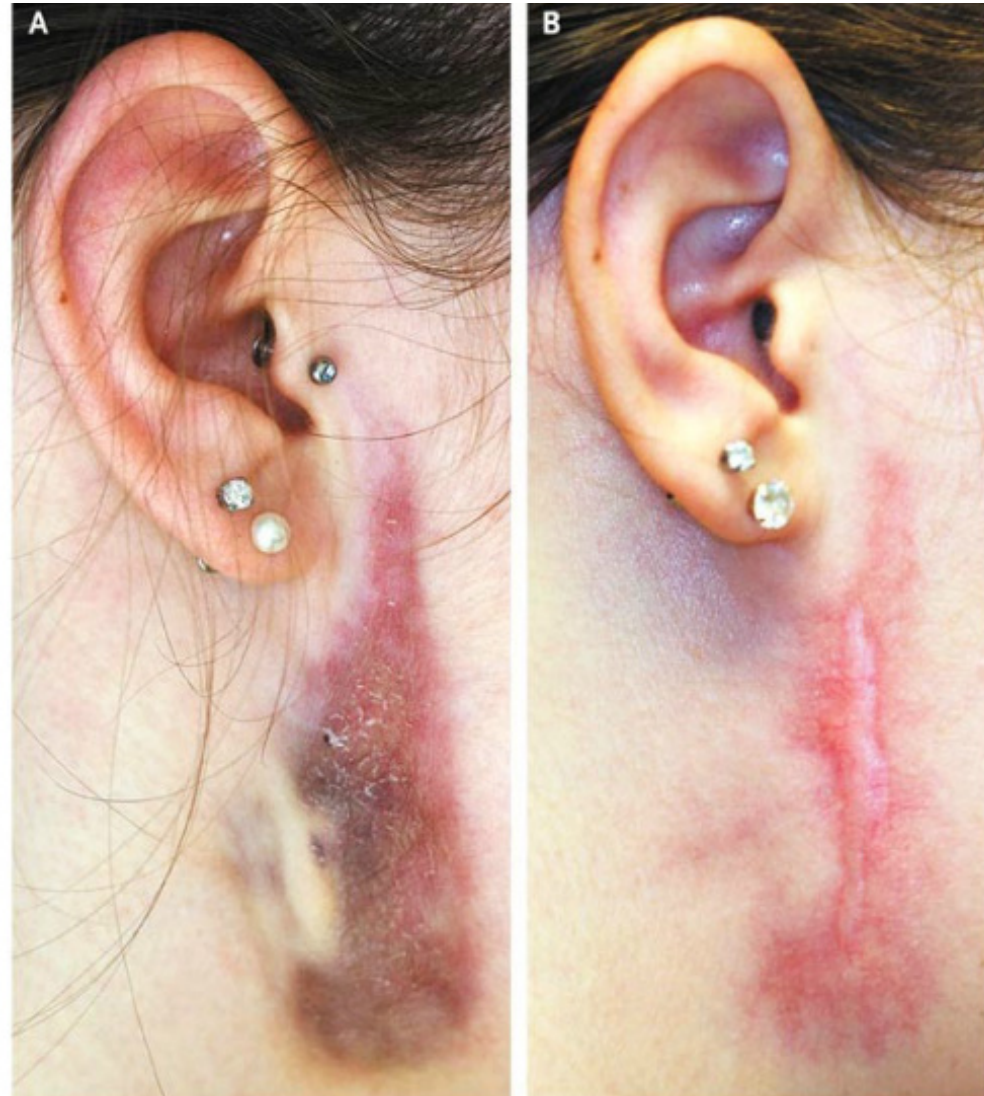Varicella Pneumonia



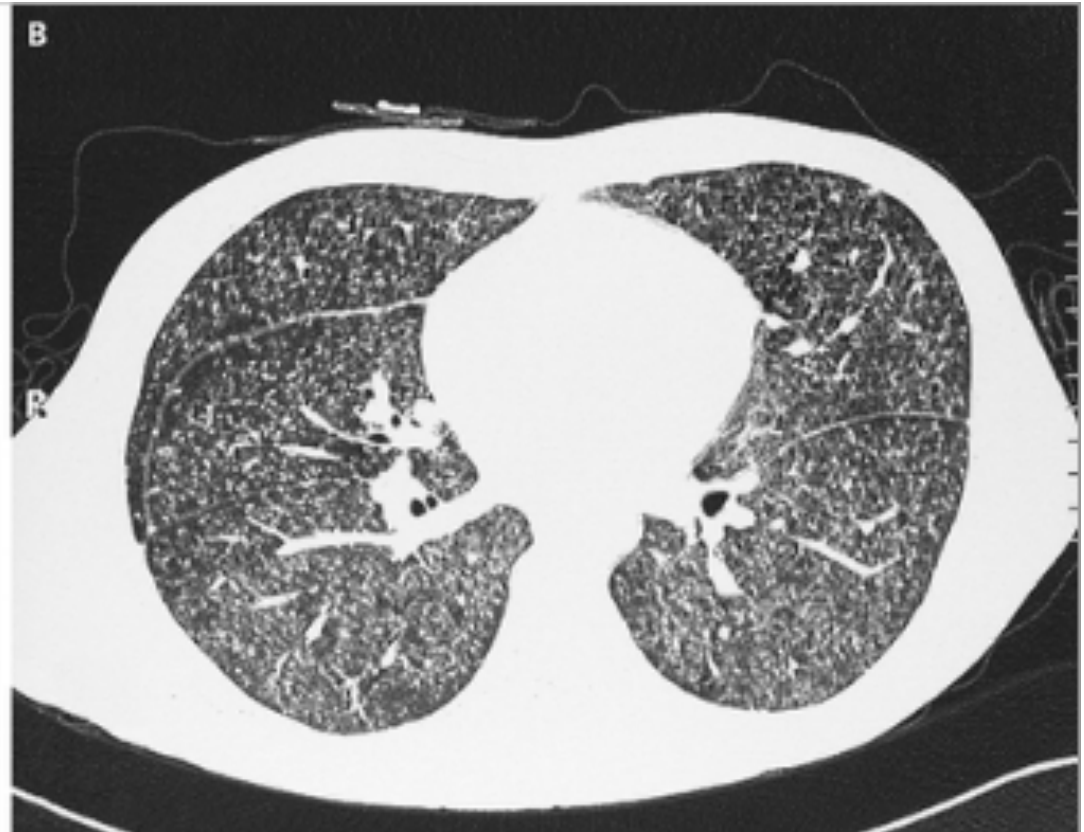
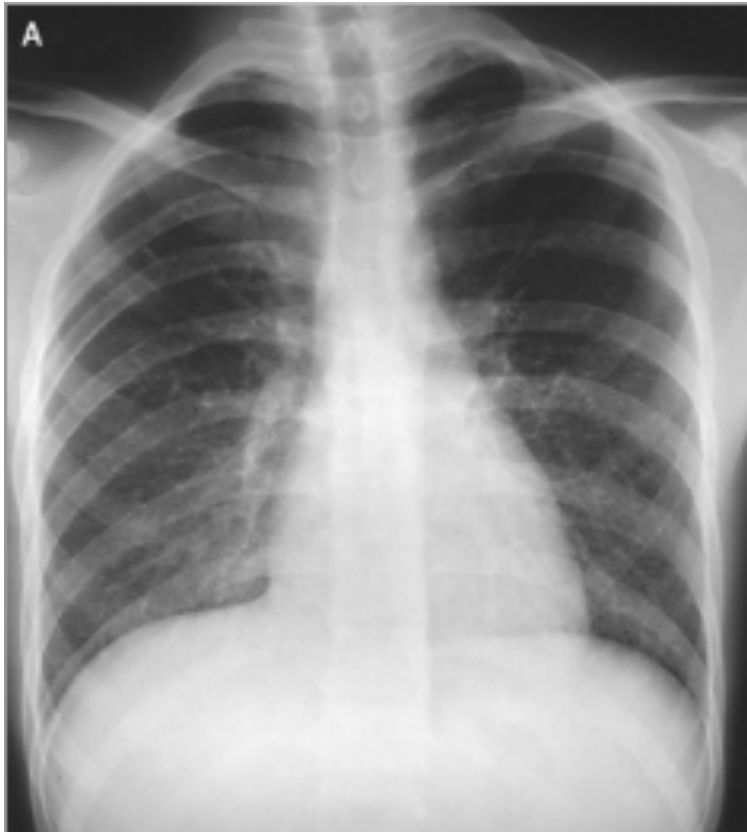Hand, Foot and Mouth Disease



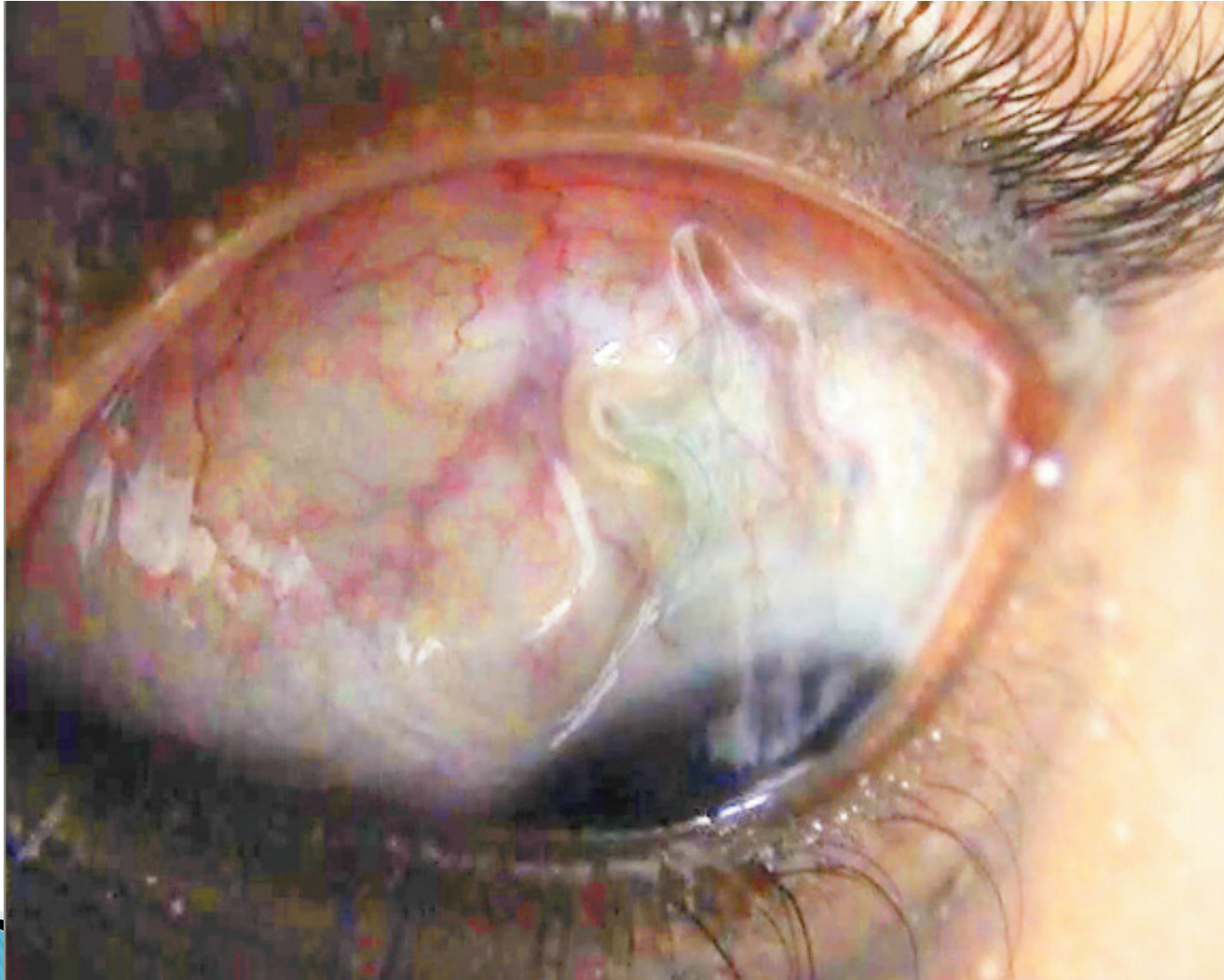
Ear Ring Associated NTB Mycobacterial Infection



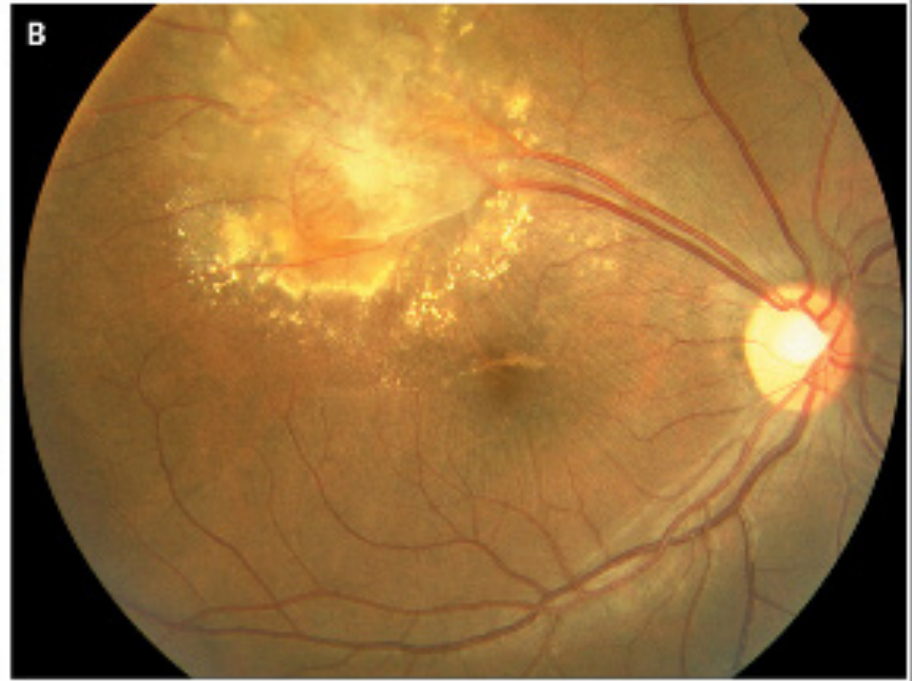
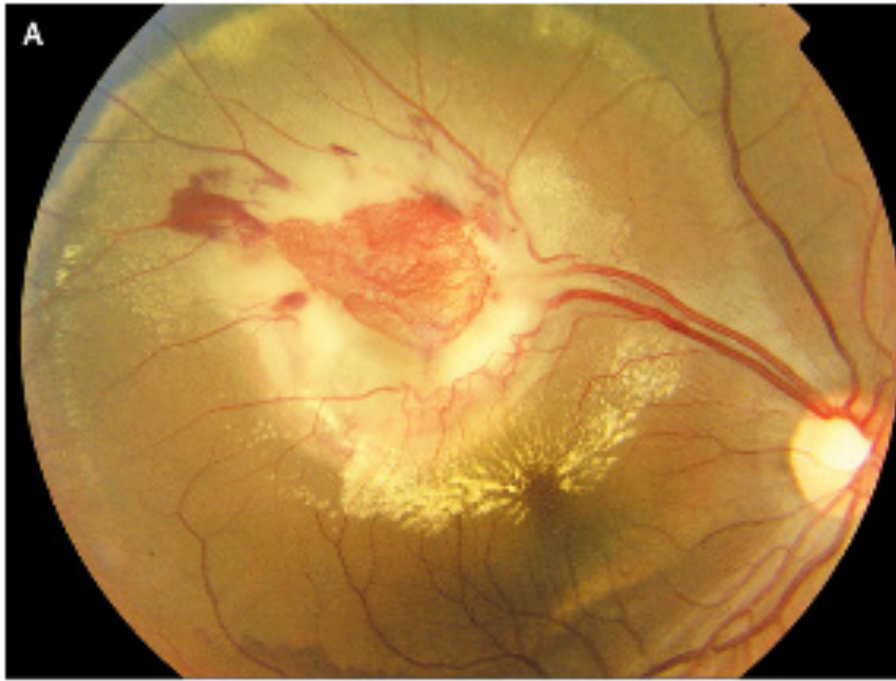
Miliary Tuberculosis



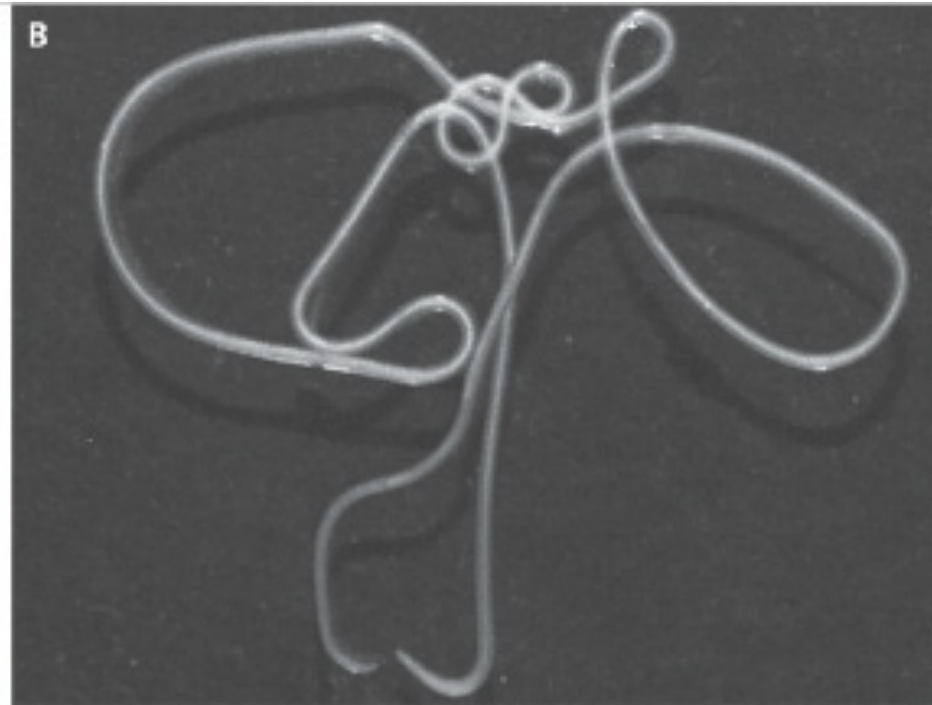
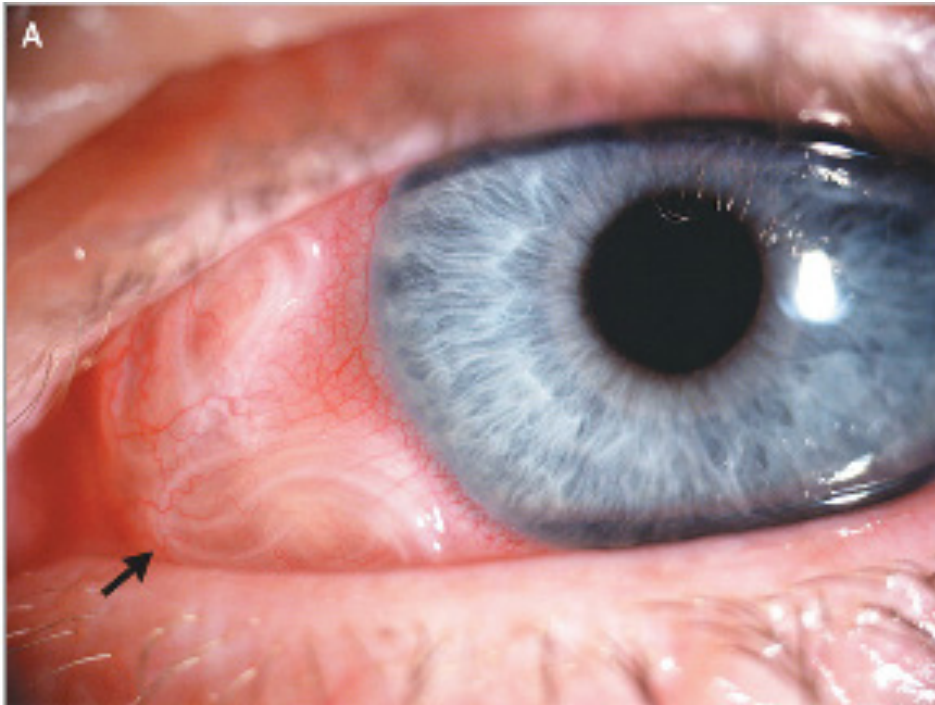Ocular Loiasis



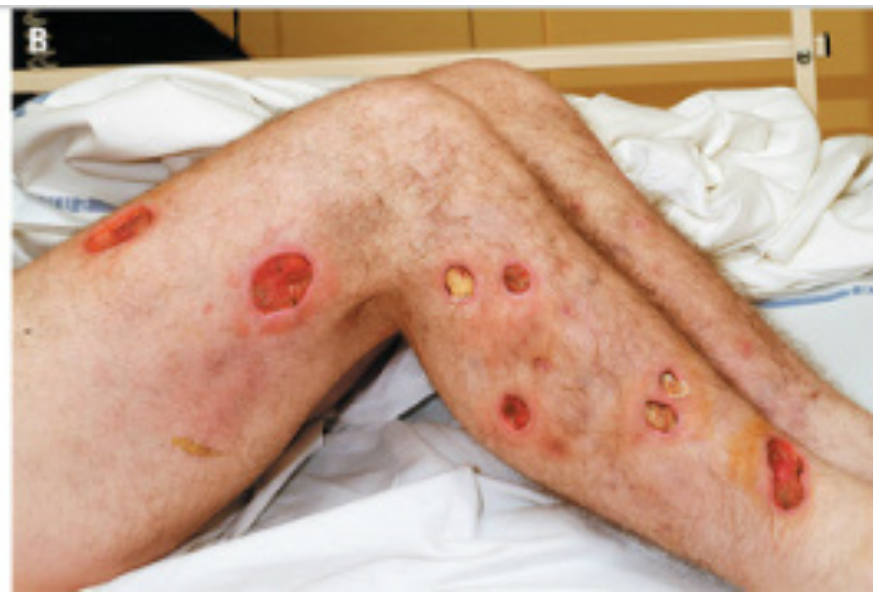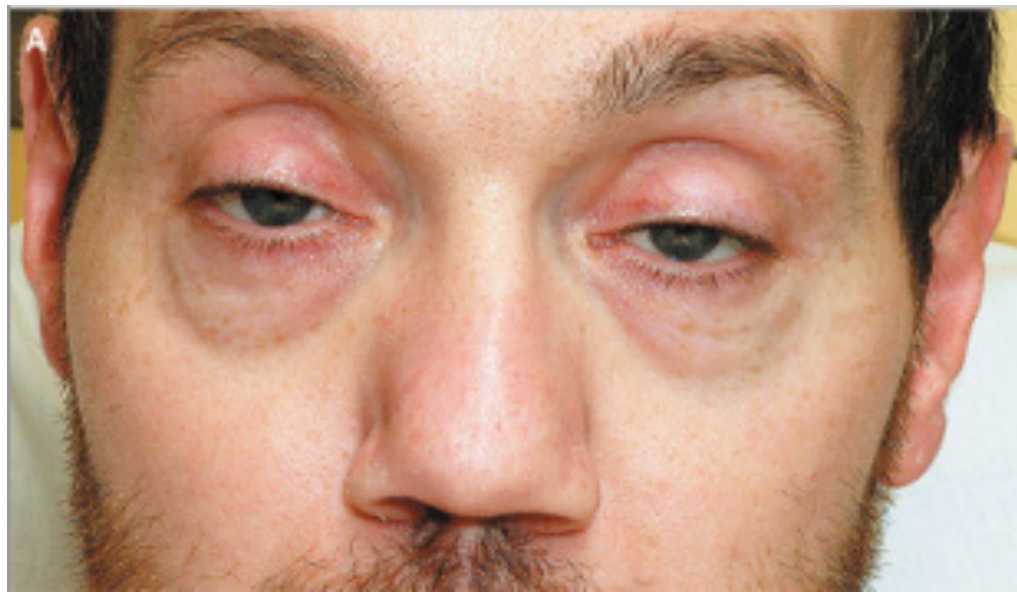TB Chorioretinal Granuloma



Dirofilaria repens



Wound Botulism



Tinea

